Downloaded from bjo.bmj.com on 10 February 2009

Twelve-month short-term safety and visual acuity results from a multicentre, prospective study of epiretinal strontium-90 brachytherapy with bevacizumab for the treatment of subfoveal choroidal neovascularisation secondary to age-related macular degeneration

Marcos P. Ávila, Michel Eid Farah, Arturo Santos, João Paulo Duprat, Benjamin W. Woodward and Jeff Nau

Br. J. Ophthalmol. published online 19 Nov 2008;
doi:10.1136/bjo.2008.145912

Updated information and services can be found at:
http://bjo.bmj.com/cgi/content/abstract/bjo.2008.145912v1

These include:

Rapid responses You can respond to this article at:
http://bjo.bmj.com/cgi/eletter-submit/bjo.2008.145912v1

Email alerting service Receive free email alerts when new articles cite this article - sign up in the box at the top right corner of the article

Notes

Online First contains unedited articles in manuscript form that have been peer reviewed and accepted for publication but have not yet appeared in the paper journal (edited, typeset versions may be posted when available prior to final publication). Online First articles are citable and establish publication priority; they are indexed by PubMed from initial publication. Citations to Online First articles must include the digital object identifier (DOIs) and date of initial publication.

To order reprints of this article go to:
http://journals.bmj.com/cgi/reprintform

To subscribe to *British Journal of Ophthalmology* go to:
http://journals.bmj.com/subscriptions/

Downloaded from bjo.bmj.com on 10 February 2009
BJO Online First, published on November 19, 2008 as 10.1136/bjo.2008.145912

Twelve-month short-term safety and visual acuity results from a multicentre prospective study of epiretinal strontium-90 brachytherapy with bevacizumab for the treatment of subfoveal choroidal neovascularisation secondary to age-related macular degeneration

M P Ávila,[1] M E Farah,[2] A Santos,[3] J P Duprat,[2] B W Woodward,[4] J Nau[4]

[1]Centro de Referência em Oftalmologia, Universidade Federal de Goiás, Goiânia, Brazil; [2]Departamento de Oftalmologia, Universidade Federal de São Paulo, São Paulo, Brazil; [3]Director, Centro de Retina Médica y Quirúrgica, S.C., Centro Medico Puerta de Hierro, Universidad de Guadalajara, Guadalajara, Jalisco Mexico; [4]NeoVista, Inc., Fremont, California, USA

Abbreviated Title: Epiretinal brachytherapy with bevacizumab for wet AMD

Key words: Age-related macular degeneration; subfoveal choroidal neovascularisation; epiretinal brachytherapy; bevacizumab; beta radiation

Abbreviations: AMD, age-related macular degeneration; BCVA, best-corrected visual acuity; CNV, choroidal neovascularisation; ETDRS, Early Treatment Diabetic Retinopathy Study; ITT, intent to treat; OCT, optical coherence tomography; VEGF, vascular endothelial growth factor

Correspondence to: Dr. M P Ávila, Centro Brasileiro de Cirurgia de Olhos, CEP 74210-010 Goiânia – Goiás, Brazil; Phone: +55 62 3252 5566; Fax: +55 62 3252 5500; Email: retina@cbco.com.br

Copyright Article author (or their employer) 2008. Produced by BMJ Publishing Group Ltd under licence.

Downloaded from bjo.bmj.com on 10 February 2009

ABSTRACT

Background/aims
This study evaluated the short-term safety and feasibility of epiretinal strontium-90 brachytherapy delivered concomitantly with intravitreal bevacizumab for the treatment of subfoveal CNV due to AMD for 12 months. Three-year follow up is planned.

Methods
In this prospective, nonrandomised, multicentre study, 34 treatment-naïve patients with predominantly classic, minimally classic, and occult subfoveal CNV lesions received a single treatment with 24 Gy beta radiation (strontium-90) and 2 injections of the anti-VEGF antibody bevacizumab. Adverse events were observed. BCVA was measured using standard ETDRS vision charts.

Results
Twelve months after treatment, no radiation-associated adverse events were observed. In the intent-to-treat (ITT) population, 91% percent of patients lost <3 lines (15 ETDRS letters) of vision at 12 months, 68% improved or maintained their BCVA at 12 months, and 38% gained ≥3 lines. The mean change in BCVA observed at month 12 was a gain of 8.9 letters.

Conclusion
The safety and efficacy of intraocular, epiretinal brachytherapy delivered concomitantly with anti-VEGF therapy for the treatment of subfoveal CNV secondary to AMD was promising in this small study population. Long-term safety will be assessed for 3 years. This regimen is being evaluated in a large, multicentre, phase III study.

Downloaded from bjo.bmj.com on 10 February 2009

INTRODUCTION

Therapies proven to be effective in the treatment of choroidal neovascularisation (CNV) secondary to age-related macular degeneration (AMD) include laser treatment, photodynamic therapy, and anti–vascular endothelial growth factor (anti-VEGF) antibodies.[1] Radiation therapy has been previously studied as a treatment for neovascular AMD.[2-4] The use of radiation as a treatment modality is based on the concept that neovascular AMD is analogous to a proliferative wound healing process,[5] and proliferating cells are sensitive to the effects of radiation.[6] CNV complexes are histologically comprised of retinal pigment epithelium, vascular endothelium, local inflammatory cell populations, and fibroblasts.[7] The effects of radiation on normal and injured vasculature have been explored in multiple animal and human studies,[8, 9] mostly from the cardiovascular arena. Ionising radiation acts by forming free radicals (primarily from water molecules) that cause irreparable damage to the DNA backbone [10] and disrupt protein synthesis. The irradiated cell is unable to replicate;[6] however, it does not lose its cellular integrity or undergo necrosis. Radiation has been shown to induce endothelial cell loss in vivo [9] and reduce fibroblast proliferation and collagen deposition in vitro.[5] The apoptotic effect on the vascular endothelium and reduction in fibroblast activity of the CNV complex are not manifest with the use of anti-VEGF compounds alone.

Unlike previous studies in which large volumes of retina tissue were irradiated to achieve a therapeutic dose to the lesion, the current study used an investigational device (intraocular strontium-90 applicator) that placed the source into close proximity to the CNV complex. The rapid reduction in dose that is inherent to strontium-90 beta radiation limits exposure to the normal tissue surrounding the lesion (0.0039 Gy to the cornea, 0.0040 Gy to the conjunctiva, 0.0056 Gy to the lens, and 2.4 Gy to the optic nerve; NeoVista, Inc., data on file), allowing for normal vasculature to initiate successful repair processes and return to normal function quickly.

Anti-VEGF antibodies act by neutralising VEGF-A, a diffusible protein that promotes angiogenesis and vascular permeability.[11] Anti-VEGF agents, such as bevacizumab and ranibizumab, exert their effect rapidly in most patients by promoting a reduction or elimination of fluid;[12] however, they require repeated injections to sustain an effect. Unlike the acute response observed with anti-VEGF therapy, the mechanism of action for radiation therapy predicts a delayed response in neovascular tissues with longer duration of effect.[13, 14] As both therapies target the disease utilising different mechanisms of action, there is scientific rationale for combining the therapies to produce a more durable and potentially superior response.[15]

The current study was designed to evaluate the safety and feasibility of epiretinal brachytherapy with strontium-90, delivered concomitantly with intravitreal bevacizumab for the treatment of subfoveal CNV secondary to AMD.

MATERIALS AND METHODS

Downloaded from bjo.bmj.com on 10 February 2009

Study design

In this prospective, nonrandomised, multicentre pilot study, patients with predominantly classic, minimally classic, and occult (with no classic) CNV received a single treatment with 24 Gy brachytherapy using an investigational medical device (intraocular strontium-90 applicator; NeoVista, Inc., Fremont, California) and two injections of the anti-VEGF antibody bevacizumab. Only 1 eye per patient received the investigational treatment.

Patients were enrolled in 1 of 2 groups that varied with timing of the delivery of the first bevacizumab injection. In Group 1, the first injection was delivered at 10±4 days before surgery, and in Group 2, the first injection was delivered at the time of surgery (after radiation delivery). Patients in both Group 1 and 2 received a second injection at 1 month after surgery.

Patient eligibility criteria

Only patients who provided informed consent and signed an ethics committee–approved informed consent form were eligible for screening. To be enrolled into the study, patients had to be at least 55 years of age; have an ETDRS (Early Treatment Diabetic Retinopathy Study) best-corrected visual acuity (BCVA) of 20/40 to 20/320 (ETDRS Snellen equivalent) in the study eye; have evidence of recent lesion activity documented by fluorescein angiography; have subfoveal CNV secondary to AMD (predominantly classic, minimally classic, or occult lesion subtype); have lesions that are composed of at least 50% CNV; and have a maximum lesion size of 12 Macular Photocoagulation Study disc areas. A complete list of eligibility criteria is included in Appendix I.

Treatment

Clinical centres followed the same epiretinal brachytherapy treatment protocol as reported previously (Ávila et al, submitted 2007). The active source of beta radiation was strontium-90 (29-year half life) in equilibrium with yttrium-90 (64-minute half life), the latter being the daughter product of strontium-90 after beta decay. The radiation source was within a sealed canister, laser welded to a positioning wire that was stored within the handpiece. The position of the radioactive source was controlled by a slide mechanism attached to the positioning wire. When the mechanism was in the retracted (storage) position, the source was shielded by a Densimet (tungsten alloy) and aluminium thoreus shield. In the engaged (treatment) position, the radioactive source was deployed to the tip of a stainless steel cannula where there was minimal shielding (0.1 mm stainless steel), allowing the strontium-90/yttrium-90 radiation to treat the CNV. The cannula was plugged at the tip creating a sealed system and preventing direct contact with intraocular tissues. The radioactive material was always fully enclosed within the device and was delivered to the retina for less than 5 minutes.

Bevacizumab (Avastin®; Genentech, South San Francisco, California) was compounded by an independent pharmacy (Brazil) or within the clinic (Mexico) and delivered as 1.25 mg (0.05 mL) aliquots for intravitreal injection.

Downloaded from bjo.bmj.com on 10 February 2009

Study endpoints

Safety parameters to be evaluated included incidence and severity of ocular adverse events identified by eye examination, including imaging studies as well as visual acuity (VA). Stereo fundus photography was also reviewed. Incidence and severity of other reported adverse events were also evaluated.

Although this pilot study was not designed to determine efficacy, preliminary effectiveness was evaluated by BCVA as assessed by the ETDRS chart read at 2 m, CNV lesion size and leakage as assessed by fluorescein angiography, and retinal thickness as assessed by optical coherence tomography (OCT). Patients will be followed up for 36 months to evaluate long-term safety.

Data analysis

Data were collected on case report forms. Safety and efficacy analyses were performed on all available data from the intent-to-treat (ITT) population, which included all enrolled patients.

RESULTS

Demographics and study population

A total of 34 patients were enrolled at 3 sites in Mexico (1 site) and Brazil (2 sites) from June 2006 through April 2007 (table 1).

Table 1 Study patient demographics and baseline characteristics

Number of patients	34
Age, y	
Mean (SD)	71.8 (9.2)
Minimum, maximum	51, 91
Gender, n (%)	
Male	12 (35.3%)
Female	22 (64.7%)
Race, n (%)	
White	27 (79.4%)
Hispanic	7 (20.6%)
Lesion type, n (%)	

Downloaded from bjo.bmj.com on 10 February 2009

Predominantly classic	10 (29.4%)
Minimally classic	7 (20.6%)
Occult	17 (50%)
Mean ETDRS BCVA	
Mean (SD)	40.65 (14.7)
Minimum, maximum	19, 67
Mean Central Retinal/Lesion Thickness	
Mean (SD)	321.5 (103.0)
Minimum, maximum	583, 161

SD, standard deviation; ETDRS, Early Treatment Diabetic Retinopathy Study; BCVA, best-corrected visual acuity.

The mean age was 71.8 years (range, 51 to 91 years), consistent with the natural occurrence of the disease in the general population. There were more women than men enrolled (65% vs 35%), consistent with the natural predominance of the disease in women. Angiographic lesion classification was not equally distributed, with 50% of subjects presenting with the occult subtype.

Due to poor compliance in the timing of the first injection for Group 1, the data are inconclusive as to whether there is a difference between groups with regards to timing of the initial bevacizumab injection. Safety and efficacy data are therefore presented as a combined population of Groups 1 and 2.

Of the 34 patients enrolled, 24 met the protocol-specified eligibility criteria. Three patients had lesion sizes at baseline that were larger than 5.4 mm. Two patients did not have lesions that involved the subfoveal space. Three additional patients did not meet lesion eligibility criteria for various reasons (lesion was all scar, lesion was a serous pigment epithelial detachment, lesion was retinal vascular disease and not AMD). One patient had prior evidence of laser treatment, and 1 patient was less than 55 years of age. Although these patients did not meet the eligibility criteria, they were evaluated in both the safety and efficacy analyses (ITT population).

Safety

All adverse events are listed in table 2. In the first 12 months of follow up, there were no instances of radiation-induced toxicity or adverse events attributed to radiation exposure with the intraocular strontium-90 applicator. Adverse events reported related to the device or procedure included subretinal haemorrhage (1/34), retinal tear (1/34), subretinal fibrosis (2/34), epiretinal membrane (1/34), and cataract (6/24; 24 patients were phakic at baseline).

Downloaded from bjo.bmj.com on 10 February 2009

Table 2 Ocular adverse events reported

Adverse event	Percentage of patients	Severity*
CNV leakage	20.6% (7/34)	Moderate
Cataract	25% (6/24)†	Moderate
Retinal tear	3%(1/34)	Moderate
Subretinal fibrosis	6% (2/34)	Moderate
Increase in intraocular pressure	6% (2/34)	Moderate
Epiretinal membrane	3% (1/34)	Moderate
Conjunctivitis	3% (1/34)	Moderate
Subretinal haemorrhage	3% (1/34)	Mild
Preretinal blood	3% (1/34)	Mild
Cystoid macular edema	3%(1/34)	Mild
Tubercular uveitis	3% (1/34)	Moderate
Vitreous haemorrhage‡	3% (1/34)	Mild

*If multiple events, level of severity of the most severe event was described in the table.
†Calculated from the number of phakic patients at baseline.
‡Due to lesion progression not related to device.
CNV, choroidal neovascularisation.

The subretinal haemorrhage, reported at the time of treatment, was outside of the lesion area and deemed to be related to the device. The retinal tear, reported at 1 week, was also deemed to be related to the device. The tear occurred in a patient who had a large serous pigment epithelial detachment at the time of enrolment into the study. One case of subretinal fibrosis, reported at the 3-month follow-up visit, was deemed to be related to the vitrectomy procedure. The other case of subretinal fibrosis, reported at the 2-month follow-up visit, was deemed possibly related to both the device and the procedure. The epiretinal membrane, reported at the 3-month follow-up visit, was also deemed possibly related to both the device and the procedure. Cataract incidence was 25% (6/24) in the first 12 months of follow up (calculated from the number of phakic patients at baseline). All occurrences of cataracts were deemed to be related to the vitrectomy procedure.

Eight patients showed evidence of lesion reactivation based on OCT and fluorescein angiographic criteria and required additional injections of bevacizumab; 1 patient after the 2-month follow-up visit, 1 after the 3-month follow-up visit, 5 after the 6-month follow-up visit, and 1 after the 9-month follow-up visit. One of the patients who showed evidence of lesion reactivation after the 6-month follow-up visit showed continued evidence of lesion reactivation and received an additional injection of bevacizumab at the 9-month follow-up visit as well.

Visual acuity

At month 12, the mean change in BCVA from the baseline visit in the ITT population (all available data; N=34) treated with 24 Gy brachytherapy and bevacizumab was a gain of 8.9 letters of vision (fig 1). The peak mean BCVA for the population, a gain of over 15 letters (3 lines), was reported at the month 3 visit. This is consistent with studies of anti-

Downloaded from bjo.bmj.com on 10 February 2009

VEGF therapy, which demonstrated greatest VA improvements within the first 3 months.[11, 16, 17]

At month 12, 91% (31/34) of patients treated with 24 Gy brachytherapy and bevacizumab lost fewer than 15 letters and 68% (23/34) had stable or improved vision (fig 2). Most impressively, nearly 40% (13/34) of patients experienced a clinically significant improvement in vision at month 12, defined as a gain of 15 or more letters (3 lines).

Central retinal thickness/lesion thickness

Baseline OCT (Carl Zeiss Meditech) was performed for 94% (32/34) of patients; the mean central retinal thickness/lesion thickness (CRT/LT) was 321.5 ± 103 microns. At month 12 there was a 71.8 micron reduction in CRT/LT to 249.7 ± 81microns (fig 3) in the ITT population (last observation carried forward).

DISCUSSION

The current study evaluated the short-term safety and feasibility of combined intraocular epiretinal strontium-90 brachytherapy and bevacizumab therapy for the treatment of CNV secondary to AMD. The investigational device used in this trial delivered focal, low-dose beta radiation from a strontium-90 source to the CNV complex. Strontium-90 is a suitable isotope for the treatment of neovascular growth within the intraocular compartment since it has a limited depth of penetration and its energy rapidly dissipates as a function of distance from the source. Unlike other radiation approaches, which deliver high-doses and/or irradiate large areas of tissue, the current approach limits radiation exposure to a defined region surrounding the target tissue, with little damage to adjacent, normal tissues. Complications resulting from radiotherapy, such as radiation retinopathy, are often associated with exposure to higher doses of radiation than what was delivered in this study.[18] The threshold for radiation damage is estimated to be greater than 50 Gy,[19-21] and the dose of beta radiation used in this study is well below that level.

The safety of epiretinal brachytherapy delivered using the investigational device was previously examined in a prospective, nonrandomised, multicentre pilot study in patients with CNV secondary to AMD (eight treated with 15 Gy and 26 treated with 24 Gy) (Ávila et al, submitted 2007). These patients have now been followed for 24 months with no reports of radiation retinopathy. Consistent with those findings, there were no reports of radiation retinopathy during the first year of follow up in the current study (patients will be followed up for 36 months). Adverse events deemed to be associated with the device or the procedure included subretinal haemorrhage, retinal tear, subretinal fibrosis, epiretinal membrane, and cataract. Although the retinal tear was deemed by investigators to be related to the device, it was not noted at the time of surgery and could have been due to bevacizumab injection. The phenomenon of retinal pigment epithelial tears in patients treated with bevacizumab who have pigment epithelial detachments has been well documented in the literature.[22]

Downloaded from bjo.bmj.com on 10 February 2009

The peak mean change in BCVA for the population, a gain of over 15 letters (3 lines), was reported at the month 3 visit and stabilised at approximately 9 letters between month 6 and month 12. This same pattern of early improvement followed by a stable response was observed in a previously reported study of the device alone (Ávila et al, submitted 2007). An earlier trial evaluating combination therapy with intravitreal ranibizumab and verteporfin photodynamic therapy reported that 91% of patients receiving combination therapy lost fewer than 15 letters after 1 year and 24% gained at least 15 letters.[23] In addition, patients gained a mean of 4.9 letters from baseline, suggesting that preliminary results with combination therapy using epiretinal beta radiation therapy may be comparable to findings from other combination anti-VEGF trials.

The rationale supporting a synergistic response with a combination regimen of radiation and antiangiogenic therapy is based on a two-pronged approach for treating the CNV complex: antiangiogenic therapy inhibits growth factors present in the local region and radiotherapy kills or disables the local inflammatory cell population and eventually the endothelial cells of the neovascular vessel. Together, the combination of these two effects may allow for faster and more complete recovery of functional vision. This small pilot study showed encouraging results with a single application of epiretinal beta radiation and 2 injections of anti-VEGF antibody. Based on the outcome of this study, this combination regimen is now being evaluated in a large, multicentre, phase III study.

Downloaded from bjo.bmj.com on 10 February 2009

LICENCE FOR PUBLICATION AND COMPETING INTEREST

The Corresponding Author has the right to grant on behalf of all authors and does grant on behalf of all authors, an exclusive licence (or non exclusive for government employees) on a worldwide basis to the BMJ Publishing Group Ltd and its Licensees to permit this article (if accepted) to be published in BJO editions and any other BMJPGL products to exploit all subsidiary rights, as set out in our licence (http://bjo.bmjjournals.com/ifora/licence.pdf).

Competing Interest: Dr. Woodward and Mr. Nau are employed by NeoVista, Inc., and have a proprietary interest in the investigational device. Dr. Avila, Dr. Farah, Dr. Santos, and Dr. Duprat have no financial or non-financial competing interest to declare.

Downloaded from bjo.bmj.com on 10 February 2009

REFERENCES

1 Schmidt-Erfurth UM, Richard G, Augustin A, *et al*. Guidance for the treatment of neovascular age-related macular degeneration. *Acta Ophthalmol Scand* 2007;**85**:486-94.

2 Chakravarthy U, Houston RF, Archer DB. Treatment of age-related subfoveal neovascular membranes by teletherapy: a pilot study. *Br J Ophthalmol* 1993;**77**:265-73.

3 Finger PT, Berson A, Ng T, *et al*. Ophthalmic plaque radiotherapy for age-related macular degeneration associated with subretinal neovascularization. *Am J Ophthalmol* 1999;**127**:170-7.

4 Jaakkola A, Heikkonen J, Tommila P, *et al*. Strontium plaque irradiation of subfoveal neovascular membranes in age-related macular degeneration. *Graefes Arch Clin Exp Ophthalmol* 1998;**236**:24-30.

5 Kirwan JF, Constable PH, Murdoch IE, *et al*. Beta irradiation: new uses for an old treatment: a review. *Eye* 2003;**17**:207-15.

6 De Gowin RL, Lewis LJ, Hoak JC, *et al*. Radiosensitivity of human endothelial cells in culture. *J Lab Clin Med* 1974;**84**:42-8.

7 Grossniklaus HE, Martinez JA, Brown VB, *et al*. Immunohistochemical and histochemical properties of surgically excised subretinal neovascular membranes in age-related macular degeneration. *Am J Ophthalmol* 1992;**114**:464-72.

8 Waksman R, Bhargava B, Saucedo JF, *et al*. Yttrium-90 delivered via a centering catheter and afterloader, given both before and after stent implantation, inhibits neointima formation in porcine coronary arteries. *Cardiovasc Radiat Med* 2000;**2**:11-7.

9 Verin V, Popowski Y, de Bruyne B, *et al*. Endoluminal beta-radiation therapy for the prevention of coronary restenosis after balloon angioplasty. The Dose-Finding Study Group. *N Engl J Med* 2001;**344**:243-9.

10 Wallace SS. Enzymatic processing of radiation-induced free radical damage in DNA. *Radiat Res* 1998;**150**:S60-79.

11 Rosenfeld PJ, Brown DM, Heier JS, *et al*. Ranibizumab for neovascular age-related macular degeneration. *N Engl J Med* 2006;**355**:1419-31.

12 Heier JS, Antoszyk AN, Pavan PR, *et al*. Ranibizumab for treatment of neovascular age-related macular degeneration: a phase I/II multicenter, controlled, multidose study. *Ophthalmology* 2006;**113**:633-42.

13 Finger PT, Gelman YP, Berson AM, *et al*. Palladium-103 plaque radiation therapy for macular degeneration: results of a 7 year study. *Br J Ophthalmol* 2003;**87**:1497-503.

Downloaded from bjo.bmj.com on 10 February 2009

14 Jaakkola A, Heikkonen J, Tommila P, *et al*. Strontium plaque brachytherapy for exudative age-related macular degeneration: three-year results of a randomized study. *Ophthalmology* 2005;**112**:567-73.

15 Wachsberger P, Burd R, Dicker AP. Tumor response to ionizing radiation combined with antiangiogenesis or vascular targeting agents: exploring mechanisms of interaction. *Clin Cancer Res* 2003;**9**:1957-71.

16 Brown DM, Kaiser PK, Michels M, *et al*. Ranibizumab versus verteporfin for neovascular age-related macular degeneration. *N Engl J Med* 2006;**355**:1432-44.

17 Regillo CD, Brown DM, Abraham P, *et al*. Randomized, double-masked, sham-controlled trial of ranibizumab for neovascular age-related macular degeneration: PIER Study year 1. *Am J Ophthalmol* 2008;**145**:239-48.

18 Gragoudas ES, Li W, Lane AM, *et al*. Risk factors for radiation maculopathy and papillopathy after intraocular irradiation. *Ophthalmology* 1999;**106**:1571-7.

19 Gündüz K, Shields CL, Shields JA, *et al*. Radiation retinopathy following plaque radiotherapy for posterior uveal melanoma. *Arch Ophthalmol* 1999;**117**:609-14.

20 Jiang GL, Tucker SL, Guttenberger R, *et al*. Radiation-induced injury to the visual pathway. *Radiother Oncol* 1994;**30**:17-25.

21 Lommatzsch PK, Alberti W, Lommatzsch R, *et al*. Radiation effects on the optic nerve observed after brachytherapy of choroidal melanomas with 106Ru/106Rh plaques. *Graefes Arch Clin Exp Ophthalmol* 1994;**232**:482-7.

22 Ronan SM, Yoganathan P, Chien FY, *et al*. Retinal pigment epithelium tears after intravitreal injection of bevacizumab (avastin) for neovascular age-related macular degeneration. *Retina* 2007;**27**:535-40.

23 Heier JS, Boyer DS, Ciulla TA, *et al*. Ranibizumab combined with verteporfin photodynamic therapy in neovascular age-related macular degeneration: year 1 results of the FOCUS Study. *Arch Ophthalmol* 2006;**124**:1532-42.

Downloaded from bjo.bmj.com on 10 February 2009

FIGURE LEGENDS

Figure 1 Mean change in best-corrected visual acuity for the intent-to-treat population who received 24 Gy brachytherapy plus bevacizumab.

Figure 2 Proportion of intent-to-treat population with a loss of best-corrected visual acuity (<15 letters), unchanged or improved best-corrected visual acuity (≥0 letters), or a gain of best-corrected visual acuity (≥15 letters) after treatment with 24 Gy brachytherapy plus bevacizumab.

Figure 3 Mean change in CRT/LT as measured by OCT. The mean CRT/LT at baseline was 321.5 microns, and a mean reduction of 71.8 microns was observed at 12 months in the intent-to-treat population (last observation carried forward). CRT/LT, central retinal thickness/lesion thickness; OCT, optical coherence tomography.

Downloaded from bjo.bmj.com on 10 February 2009

APPENDIX

Appendix I. Eligibility requirements

Patients underwent pretreatment screening examinations for eligibility; all patients presented with subfoveal CNV secondary to AMD, and informed consent was obtained from those eligible and participating in the study. Only 1 eye per patient received the investigational treatment.

Inclusion criteria

1. Subfoveal, CNV secondary to AMD in study eye; lesion composition must be at least 50% CNV
2. Evidence of activity of CNV as documented by fluorescein angiography (FA) in study eye
3. In the opinion of the investigator, the subject is a candidate for treatment bevacizumab
4. Lesion size (greatest linear dimension of entire lesion, not only CNV component) ≤5.4 mm and ≤12 Macular Photocoagulation Study disc areas in study eye
5. BCVA no better than 20/40 (Snellen equivalent) but no worse than 20/320 in the study eye
6. Age 55 years or older

Exclusion criteria

1. Prior or concurrent subfoveal CNV therapy including thermal laser photocoagulation (with or without photographic evidence), photodynamic therapy, intravitreal or subretinal steroids, transpupillary thermotherapy, and systemic or intravitreal antiangiogenic agents in study eye (Note: this includes patients with no known history, but with photographic evidence of prior therapy)
2. Subjects on chronic systemic corticosteroid or other immunosuppressive therapy that may affect wound healing (eg, subjects who have undergone chemotherapy within the last 6 months), and any immunocompromised subjects (eg, positive for human immunodeficiency virus)
3. History of optic neuritis
4. Evidence of significant subretinal fibrosis in study eye
5. CNV not secondary to AMD in study eye
6. Uncontrolled intraocular pressure in the treatment eye (can be controlled with medications)
7. Presence of media opacities that prevent adequate visualisation of the posterior pole
8. Presence of other ocular diseases that could cause a decrease in vision (eg, glaucoma, ocular histoplasmosis, or degenerative myopia) in the study eye
9. Presence of type 1 or type 2 diabetes mellitus
10. BCVA 20/800 or worse in the fellow eye

Downloaded from bjo.bmj.com on 10 February 2009

11. Previous intraocular surgery, excluding cataract surgery. If the subject has had cataract surgery in the study eye, it must have been >2 months prior to entry into the study
12. Previous head or neck radiation treatment
13. Women who are pregnant, lactating, or of childbearing potential
14. Known sensitivity or allergy to fluorescein
15. Known sensitivity or allergy to bevacizumab
16. Current participation in another drug or device clinical trial, or participation in such a clinical trial within the last year
17. History of use of drugs with known macular toxicity, including
    - chloroquine (Aralen®, an anti-malarial drug)
    - hydroxychloriquine (Plaquenil®)
    - phenothiazines, eg,
        - chlorpromazine (Thorazine®)
        - thioridazine (Mellaril®)
        - fluphenazine (Prolixin®)
        - perphenazine (Trilafon®)
        - trifluoperazine (Stelazine®)
18. Requiring current anticoagulation therapy at the time of surgery
19. Suspected or confirmed Creutzfeldt-Jakob disease
20. Unwilling or unable to give informed consent or to comply with required follow up

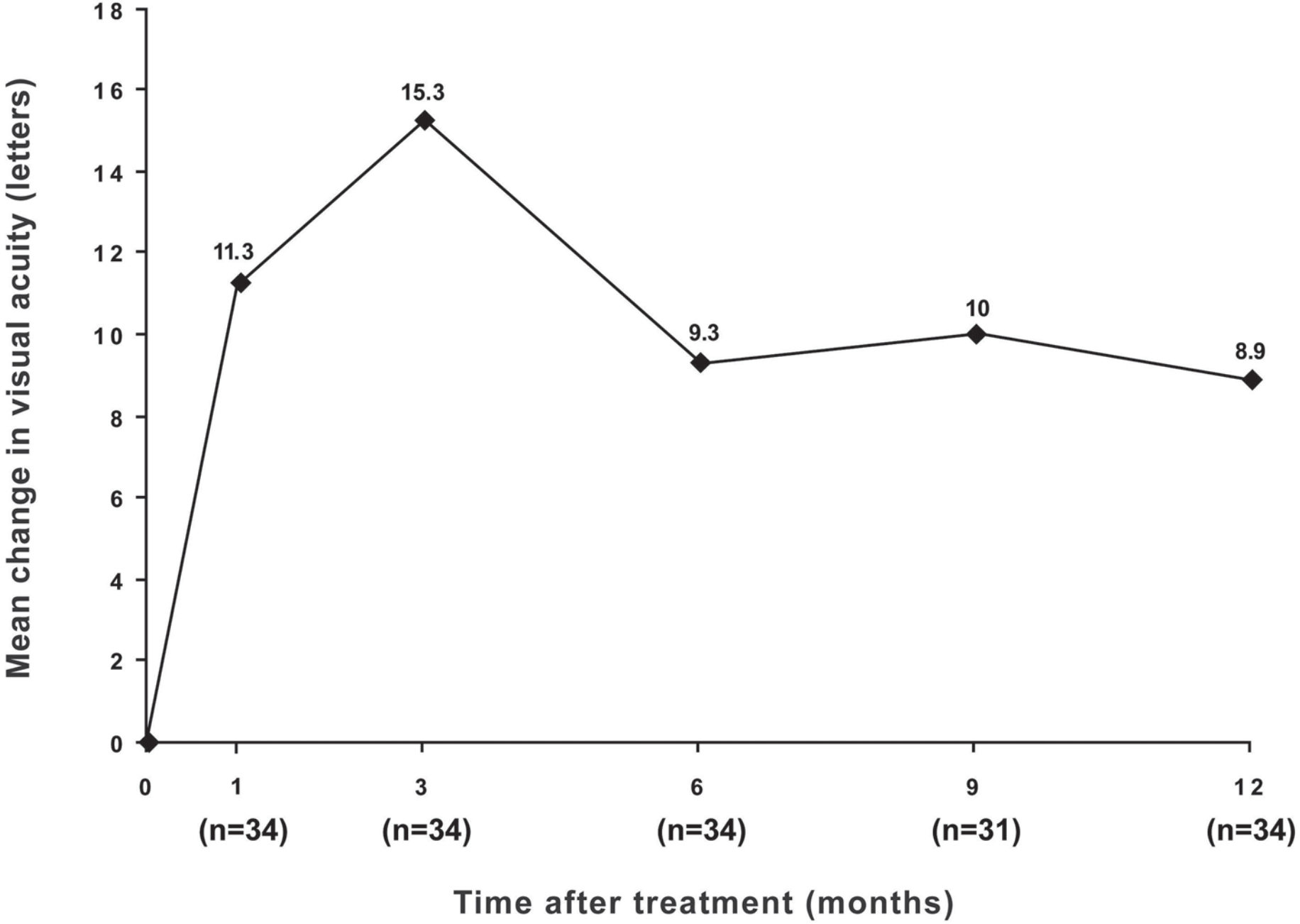
Mean change in visual acuity (letters)
18
16
14
12
10
8
6
4
2
0
15.3
11.3
9.3
10
8.9
0
1
3
6
9
12
(n=34)
(n=34)
(n=34)
(n=31)
(n=34)
Time after treatment (months)

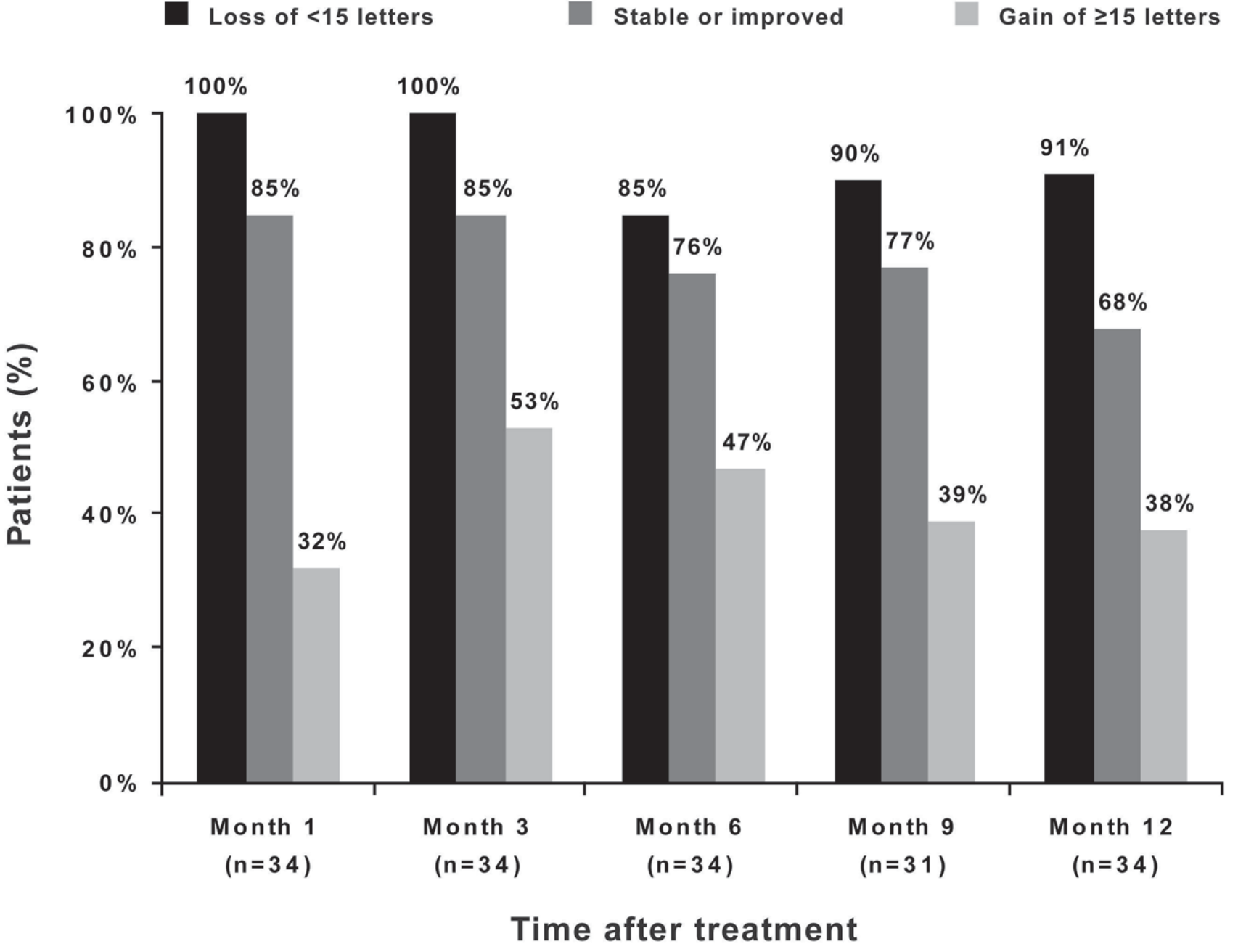
Loss of <15 letters
Stable or improved
Gain of ≥15 letters
Patients (%)
100%
80%
60%
40%
20%
0%
100%
85%
32%
100%
85%
53%
85%
76%
47%
90%
77%
39%
91%
68%
38%
Month 1 (n=34)
Month 3 (n=34)
Month 6 (n=34)
Month 9 (n=31)
Month 12 (n=34)
Time after treatment

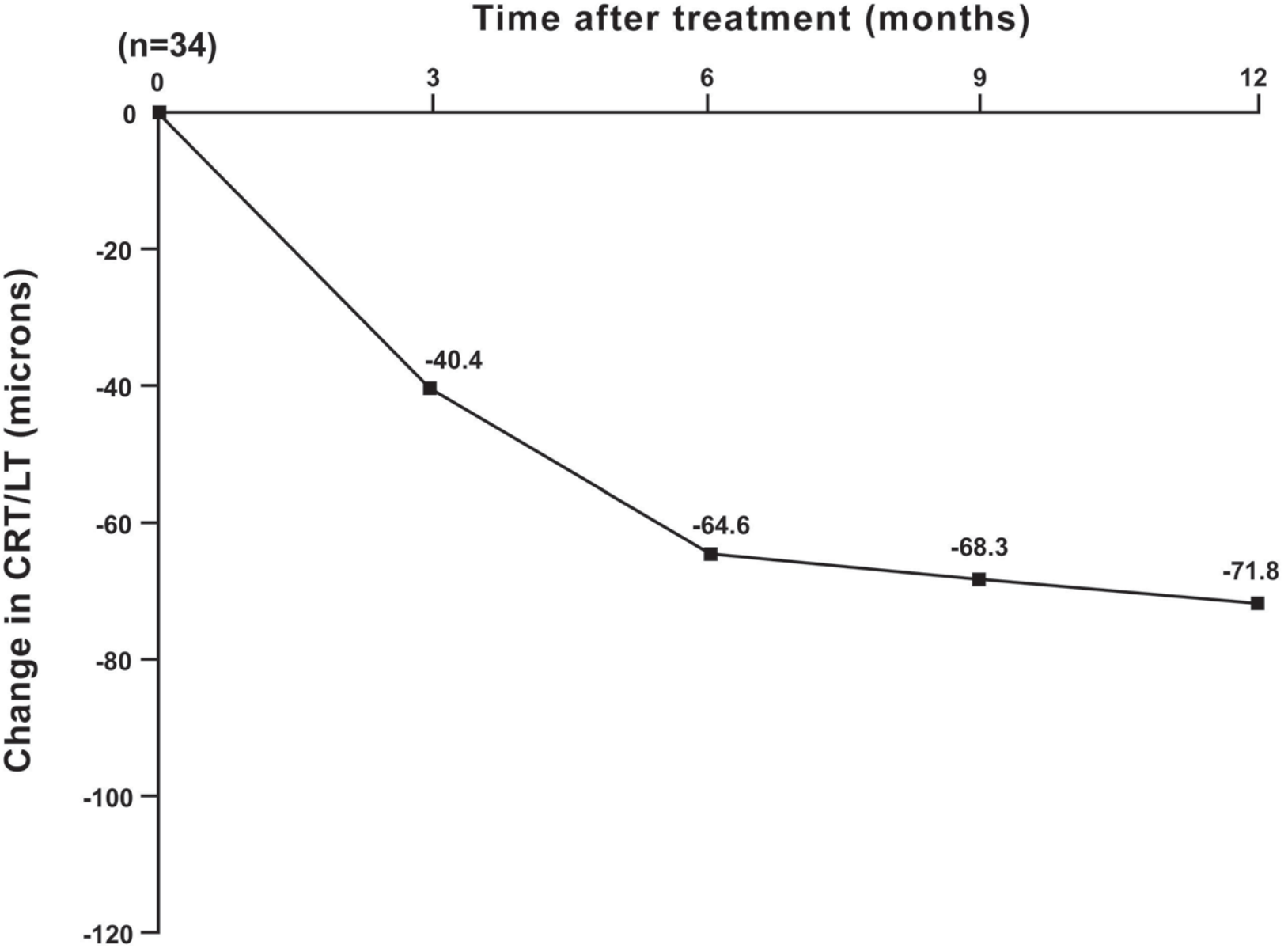
Time after treatment (months)
(n=34)
0
3
6
9
12
0
-20
-40
-60
-80
-100
-120
Change in CRT/LT (microns)
-40.4
-64.6
-68.3
-71.8